



CASE REPORT

Open Access

# Myxolipoma in the tongue - A clinical case report and review of the literature

Shigehiro Ono<sup>1†</sup>, Majeed Rana<sup>3\*†</sup>, Masaaki Takechi<sup>1</sup>, Ikuko Ogawa<sup>2</sup>, Gaku Okui<sup>1</sup>, Yoshitsugu Mitani<sup>1</sup>, Nils-Claudius Gellrich<sup>3</sup> and Nobuyuki Kamata<sup>1</sup>

## Abstract

In this article, we present our experience with a case of myxolipoma of the tongue.

Lipoma is a mesenchymal benign tumor occurring with relatively high frequency. However, myxolipoma, one of the histological variant of lipoma characterized by mature adipose tissue and abundant mucoid substances, in the oral cavity is quite rare.

The patient was a 52-year-old man who noticed a painless mass on the left border of tongue about 2 years ago. The lesion was noted at a complete medical checkup, and the patient was admitted to our institution for detailed examination. The mass was a palpable, soft and elastic nodule, 15 mm in diameter, covered with normal mucosa in the left inferior aspect of the tongue. The border of the tumor was well-defined, and computed tomography (CT) revealed a fat density within the mass. On the basis of these findings, the tumor was clinically diagnosed as lipoma and was excised under general anesthesia. Histopathologically, the tumor was a well-defined lobulated mass surrounded by a thin fibrous capsule within the muscle of the tongue. The tumor was diagnosed as myxolipoma because it consisted of solid proliferation of mature adipocytes replaced by abundant mucoid substances. The post operative course was uneventful, and there was no evidence of recurrence 4 years after surgery.

**Keywords:** Myxolipoma, Tongue benign tumor, Lipoma

## Background

Lipoma is the most common neoplasms arising from fat tissue. They are usually having the character of slow-growing, soft and silent masses. Angiolipoma, spindle cell lipoma, myelolipoma, chondrolipoma and myolipoma are some histologic variants of lipomas. Myxolipoma is a lipoma admixed with abundant mucoid substances and is considered to be a lipoma with a high degree of myxoid change [1,2].

However mixolipoma is infrequently observed as neoplasm in the trunk, it rarely occurs in oral region. Only fourteen cases of involving the oral regions, including tongue, buccal mucosa, and lowerlip have been reported in the English literature [1-4]. The incidence rate in the tongue, the buccal mucosa and the lower lip was almost

equal. In this report, the authors present the clinical and histological features of mixolipoma excised from the tongue with review of the literature.

## Case report

A 52-year-old man was referred for a painless mass of the left lateral tongue. He had been aware of the mass for about 2 years previously, but had not sought medical attention. Three months before his first visit, he was found to have this mass at a general checkup. There is nothing special in his previous medical or familial history.

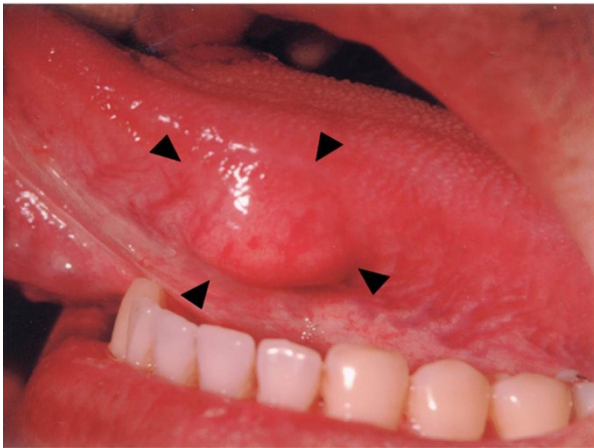Intraoral examination revealed a solitary, 15 × 15 mm-sized mass on the left border of the tongue (Figure 1). The mass covered with normal mucous membrane was elastic, soft, and movable. Its circumference was not indurated, and the patient felt no tenderness or spontaneous pain. External to the oral cavity, his face was symmetrical, and there were no swollen lymph nodes or tenderness in the neck.

\* Correspondence: rana.majeed@mh-hannover.de

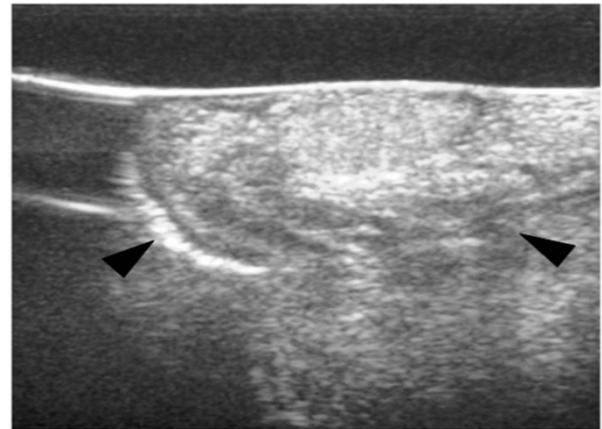
† Contributed equally

<sup>3</sup>Department of Cranio-Maxillo-Facial Surgery, Hannover Medical School, Germany

Full list of author information is available at the end of the article



**Figure 1** Clinical photograph of the lesion on the margin of the tongue (anterior surface, 15 × 15 mm).



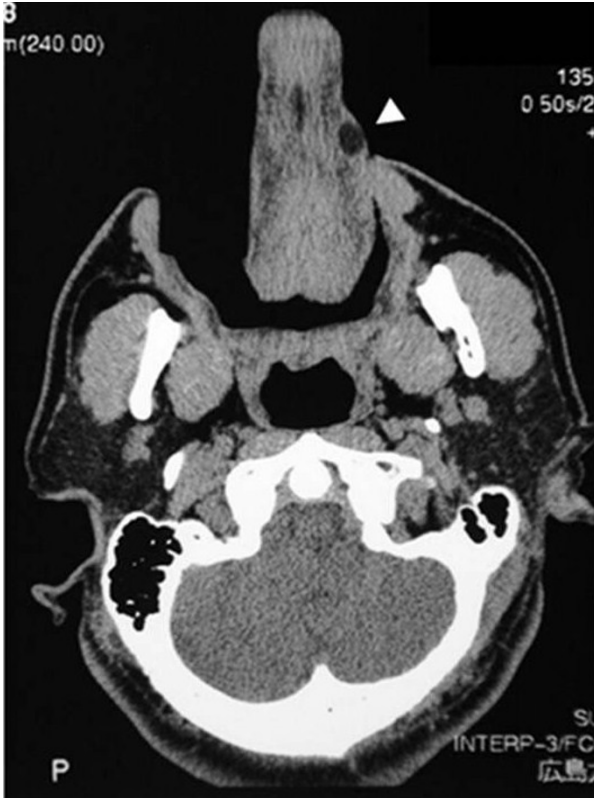**Figure 3** Echography showed a 15 × 13 × 8 mm dense highly echoic tumor.

CT showed a 15 mm-sized well-defined lesion with fat concentration inside on the left border of the tongue (Figure 2). Echography showed a 15 × 13 × 8 mm dense highly echoic tumor (Figure 3).

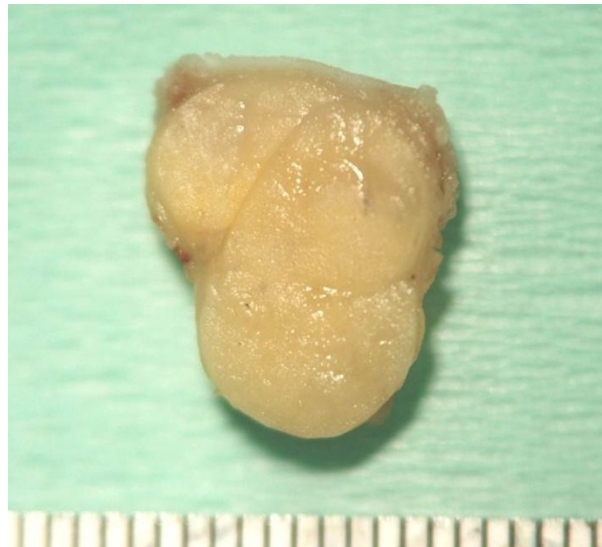On the basis of these findings, the tumor was clinically diagnosed as a benign lingual tumor (lipoma) and was

excised under general anesthesia. The mass was well demarcated and was easily separated from the surrounding tissue.

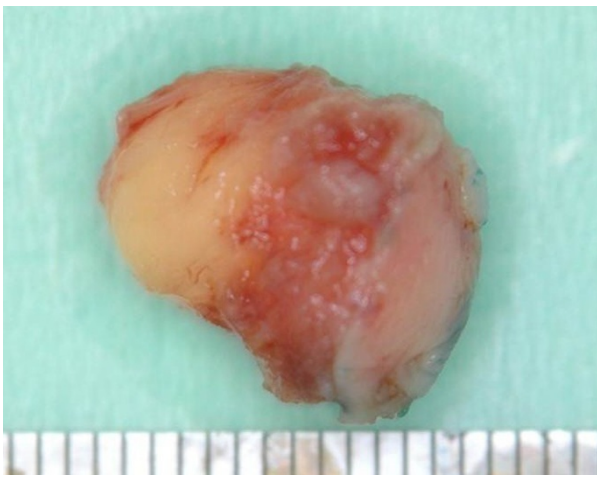
The excised mass was elastic-soft and yellowish-white and showed lobulation on its cut surface (Figure 4, 5). Histopathologically, the tumor was encapsulated and lobulated by a thin fibrous tissue (Figure 6). It was composed of solid proliferation of mature adipocytes admixed with abundant mucoid substances positively stained with alcian blue (Figs. 7, 8, 9). The myxoid areas contained scattered short-spindle smaller cells (Figure 8). Lipoblasts were not present and cellular atypia and mitotic figures were not found. A diffuse plexiform capillary network was not prominent.



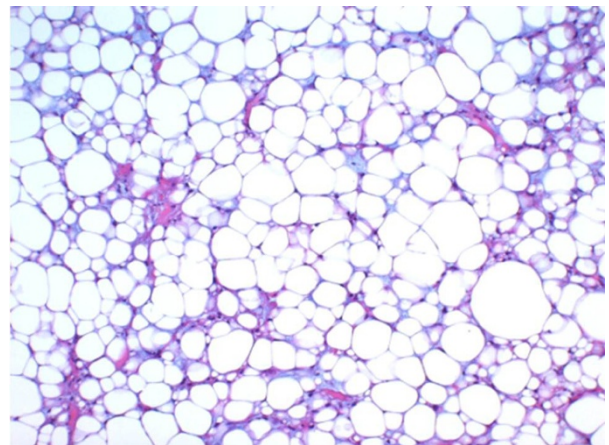
**Figure 2** CT revealed a mass at the left side and the edge of the tongue.



**Figure 4** The surgical specimen measured 1.4 cm in its greatest dimension.



**Figure 5** Cut surface was yellowish-white and lobulated.



**Figure 7** It was composed of solid proliferation of mature adipocytes.

Immunohistochemically, the tumor cell expressed S-100 protein and were negative for CD34 and bcl-2 (Figure 10, 11, 12). Final diagnosis of myxolipoma was made.

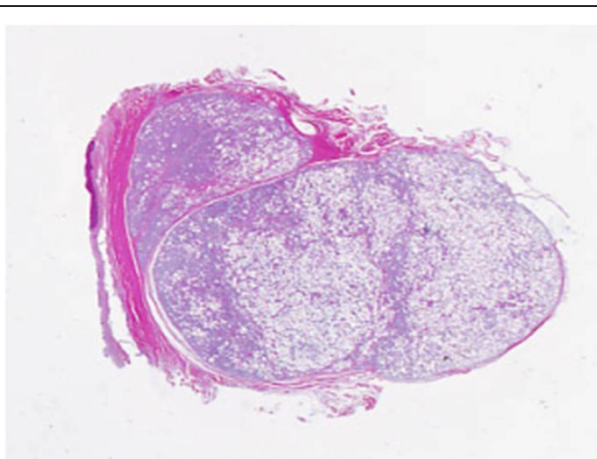
Postoperatively, there has been no lingual dysfunction or any particular problems. The post operative course was uneventful, and there was no evidence of recurrence 4 years after surgery.

### Discussion

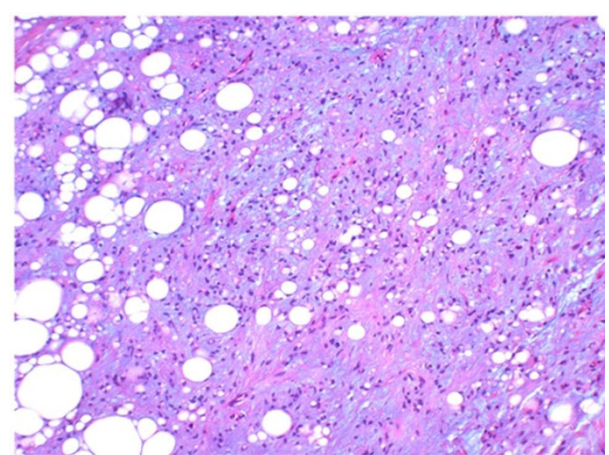
Although lipoma represents the most common mesenchymal tumor, its occurrence in the oral and maxillofacial regions is not frequent. As lipomas are occasionally altered by an admixture of other mesenchymal elements, the microscopic variants have been described, including fibrolipoma, sclerotic lipoma, chondrolipoma, osteolipoma, myolipoma and angiomyxolipoma. Myxolipoma is a lipoma admixed with abundant

mucoïd substances and is considered to be a lipoma with a high degree of mucoïd change[1,2]. The mucoïd substances are positively stained with alcian blue and are digested by hyaluronidase. Only 14 cases of this variant involving the oral regions have been reported in the English literature (Table 1). Ages ranged from 30 to 70 years. The incidence rate in the tongue, the buccal mucosa and the lower lip was almost equal.

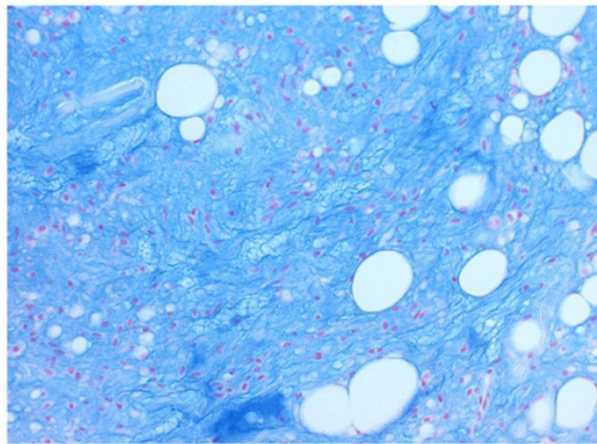
Myxolipoma has to be distinguished from benign and malignant lipomatous tumors with abundant mucoïd substances, such as chondrolipoma, spindle cell lipoma with mucoïd changes and mucoïd liposarcoma. Chondrolipoma shows nest-like or cord-like growth of lipoblasts, and its mucoïd matrix is resistant to hyaluronidase[5]. Spindle cell lipoma with mucoïd change includes CD34-positive and bcl-2-positive



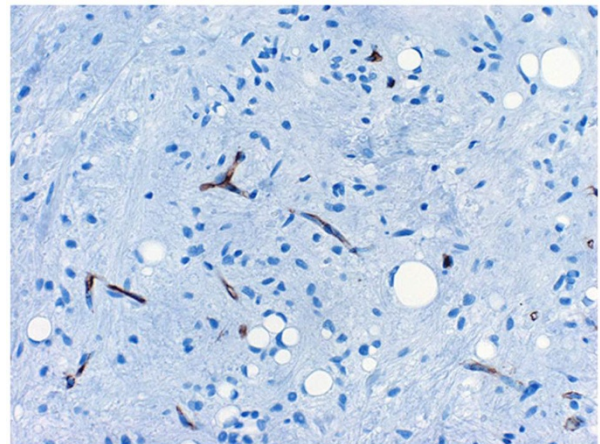
**Figure 6** Photomicrograph of the tumor was encapsulated and lobulated by a thin fibrous tissue (a).



**Figure 8** The solid proliferation replaced by abundant basophilic mucoïd substances containing short-spindle smaller cells.



**Figure 9** The matrix showed strong positivity with alcian-blue.



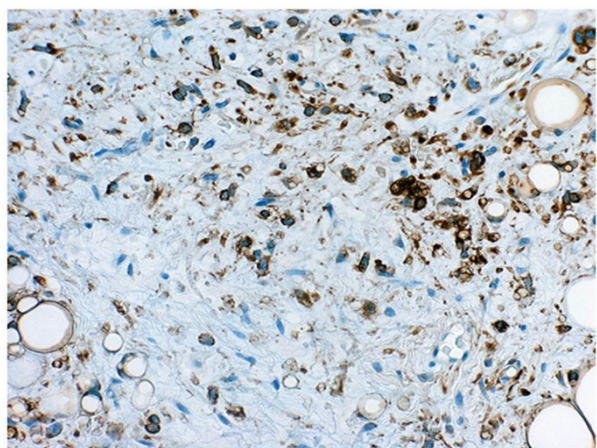
**Figure 11** The mature adipocytes and the short-spindle smaller cells were negative for CD34. And endothelial cells were positive for CD34.

spindle cells, which develop on endocapillary cells [6]. Myxoid liposarcoma is a malignant tumor that includes atypical lipoblasts and is characterized by a rich capillary network [7]. Clinical and histopathological findings of the present case are summarized as follows. The tumor was encapsulated and lobulated by a thin fibrous tissue and was composed of a mixture of a solid growth of mature adipocytes and areas rich in mucoid substances positively stained with alcian-blue and digestible by hyaluronidase. Immunohistochemical analysis showed that short spindle cells in mucoid substances in addition to mature adipocytes are positive for S-100 and negative for CD34 and bcl-2 [6]. There were no malignant features including lipoblast and an abundant capillary network [7]. Therefore, we finally diagnosed the present tumor as myxolipoma.

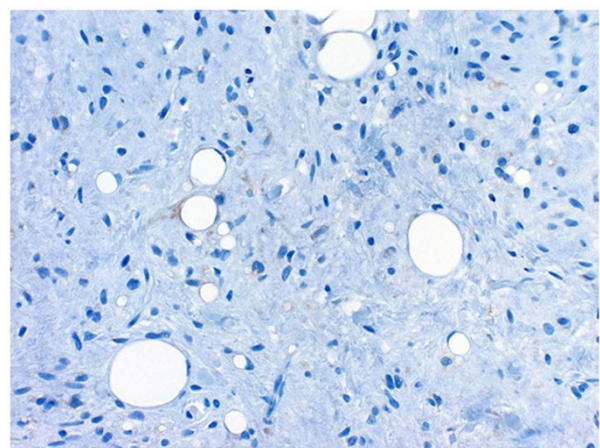
As for treatment, surgical excision becomes first choice [1-4]. There have been no reports of relapse in any of the reports of myxolipoma occurring in the entire body, whether within the oral cavity, on the larynx [8], on the thigh [9], on the skin [10], or in the cervicome-diastinum [11]; thus, we consider myxolipoma to carry a relatively benign prognosis. In the present case, for the 4 postoperative years until the present, the patient has suffered no relapse, and he is making satisfactory progress.

#### Consent statement

Written informed consent was obtained from the patient for publication of this case report and accompanying



**Figure 10** Immunohistochemical staining patterns. The mature adipocytes and the short-spindle smaller cells were strongly positive for S-100 protein



**Figure 12** Immunohistochemical staining patterns showed that the mature adipocytes and the short-spindle smaller cells were negative for bcl-2.

**Table 1 Clinical feature of reported patients with Myxolipoma in oral cavity**

Patient's ID	Clinical feature				
	age/sex	site	treatment	progress	author
1	52 male	tongue	resection	unknown	Auband JR[1]
2	70 female	tongue	resection	no relapse	Chen[2]
3	42 male	tongue	resection	no relapse	
4	30 male	buccal mucosa	resection	no relapse	
5	57 male	buccal mucosa	resection	no relapse	
6	unknown	buccal mucosa	resection	no relapse	Said-Al-Naief N[3]
7	unknown	tongue	resection	no relapse	
8	unknown	tongue	resection	no relapse	
9	unknown	lower lip	resection	no relapse	
10	unknown	lower lip	resection	no relapse	
11	unknown	lower lip	resection	no relapse	
12	unknown	lower lip	resection	no relapse	
13	unknown	gingiva	resection	no relapse	
14	55 male	buccal mucosa	resection	no relapse	Studart-Soares EC[4]

images. A copy of the written consent is available for review by the Editor-in-Chief of this journal.

### Funding

The article processing charges are funded by the Deutsche Forschungsgemeinschaft (DFG), "Open Access Publizieren".

### Author details

<sup>1</sup>Department of Oral and Maxillofacial Surgery, Division of Cervico-Gnathostomatology, Graduate School of Biomedical Sciences, Hiroshima University, Japan. <sup>2</sup>Center of Oral Clinical Examination, Hiroshima University Hospital, Kasumi 1-2-3, Minami-ku, Hiroshima, Japan. <sup>3</sup>Department of Cranio-Maxillo-Facial Surgery, Hannover Medical School, Germany.

### Authors' contributions

SO, MR, MT, IO, GO, YM, NCG and NK conceived of the study and participated in its design and coordination. SO and MR drafted the manuscript and contributed equally to this work. MR, NCG and NK were involved in revising the manuscript. All authors read and approved the final manuscript.

### Competing interests

The authors declare that they have no competing interests.

Received: 4 December 2011 Accepted: 20 December 2011

Published: 20 December 2011

### References

1. Ausband JR, Harrill JA, Pautler EE: Myxolipoma of the base of the tongue; report of a case. *Ann Otol Rhinol Laryngol* 1953, **62**:1039.
2. Chen SY, Fantasia JE, Miller AS: Myxoid lipoma of oral soft tissue. A clinical and ultrastructural study. *Oral Surg Oral Med Oral Pathol* 1984, **57**:300.
3. Said-Al-Naief N, Zahurullah FR, Sciubba JJ: Oral spindle cell lipoma. *Ann Diagn Pathol* 2001, **5**:207.
4. Studart-Soares EC, Gurgel-Costa FW, Bitu-Sousa F, Alves AP, Osterne RL: Oral lipomas in a Brazilian population: A 10-year study and analysis of 450 cases reported in the literature. *Med Oral Patol Oral Cir Bucal* 2010.
5. Darling MR, Daley TD: Intraoral chondroid lipoma: a case report and immunohistochemical investigation. *Oral Surg Oral Med Oral Pathol Oral Radiol Endod* 2005, **99**:331.

6. Imai T, Michizawa M, Shimizu H, Yamamoto N, Yura Y: Bilateral multiple spindle cell lipomas of the tongue. *Oral Surg Oral Med Oral Pathol Oral Radiol Endod* 2008, **106**:264.
7. Fanburg-Smith JC, Furlong MA, Childers EL: Liposarcoma of the oral and salivary gland region: a clinicopathologic study of 18 cases with emphasis on specific sites, morphologic subtypes, and clinical outcome. *Mod Pathol* 2002, **15**:1020.
8. Singhal SK, Virk RS, Mohan H, Palta S, Dass A: Myxolipoma of the epiglottis in an adult: a case report. *Ear Nose Throat J* 2005, **84**:728, 730, 734.
9. Tokumaru S, Kudo S, Mihara M, Matsuo Y, Takeuchi T, Koda H, Tokunaga O: Myxolipoma mimicking a cystic tumor. *Skeletal Radiol* 1996, **25**:573.
10. Cardot-Leccia N, Italiano A, Haudebourg J, Attias R, Amato D, Pedeutour F, Perrin C: Cutaneous myxolipoma with apocrine glandular differentiation: description of a new clinicopathological variant with chromosome 6p21 rearrangement. *Histopathology* 2008, **53**:361.
11. Kitami A, Suzuki T: A case report of cervicomedial lipoma. *Nippon Kyobu Geka Gakkai Zasshi* 1997, **45**:624.

doi:10.1186/1758-3284-3-50

Cite this article as: Ono et al.: Myxolipoma in the tongue - A clinical case report and review of the literature. *Head & Neck Oncology* 2011 **3**:50.

Submit your next manuscript to BioMed Central and take full advantage of:

- Convenient online submission
- Thorough peer review
- No space constraints or color figure charges
- Immediate publication on acceptance
- Inclusion in PubMed, CAS, Scopus and Google Scholar
- Research which is freely available for redistribution

Submit your manuscript at  
[www.biomedcentral.com/submit](http://www.biomedcentral.com/submit)

